

INTERESTING CASE PRESENTATION
Central Neurocytoma

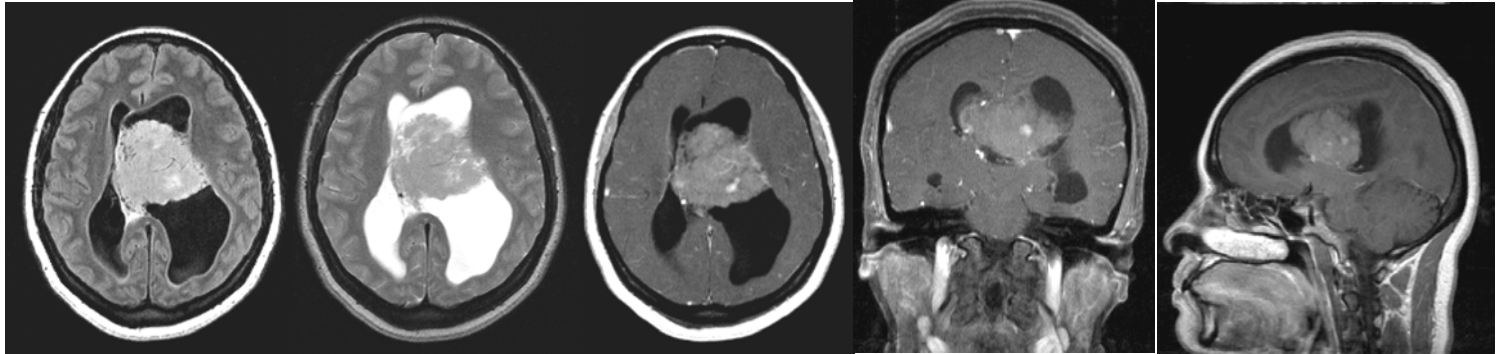


Fig. 2

Fig. 3

Fig. 4

Fig. 5

Fig. 1

CLINICAL INFORMATION: The patient is a 43-year-old female who presented with loss of balance and some memory loss. The patient was referred to AIC by **Dr. Jonathan Bedri** at Kaiser for an MRI of the brain.

MRI FINDINGS: The MRI was performed on AIC's high-field 1.5 Tesla short-bore Siemens Symphony. Fig. 1-5 depict selective axial FLAIR and T2 weighted, and post-contrast axial, coronal and sagittal T1 weighted images, respectively. There is a large 4x5x6 cm mildly enhancing heterogeneous intraventricular mass in the body of left lateral ventricle with 2 cm right-ward shift of septum pellucidum and significant obstructive hydrocephalus of lateral ventricles left greater than right due to obstruction of foramina of Monro and mild transependymal edema.

DIFFERENTIAL DIAGNOSIS: The DDX for an intraventricular mass depends on the location and age of the patient. In children, the DDX includes an intraventricular astrocytoma, ependymoma, subependymoma, primitive neuroectodermal tumor (PNET), choroids plexus papilloma, teratoma, etc. In an adult, it includes central neurocytoma, astrocytoma, ependymoma, subependymoma, meningioma, oligodendroglioma, and metastasis.

DIAGNOSIS: Given its fairly central location and heterogeneous pattern and mild enhancement, the most likely diagnosis by MRI in this age group is a central neurocytoma.

DISCUSSION: Central neurocytoma is a recently recognized brain tumor with neurosecretory granules and synapses on electron microscopy. The most common location is in the lateral ventricles near foramen of Monro. Imaging scans show an inhomogeneous, partially calcified, mildly enhancing lateral ventricular mass. It has a relatively benign biological activity.

TREATMENT: Treatment is surgical for relief of hydrocephalus and removal of tumor. The patient underwent a 16-hour transcoronal surgery at Kaiser hospital by **Dr. Najafi** and did well post-operatively. Pathology report revealed a neurocytoma as suspected by MRI.

For more information, please call me at 661-949-8111.

Ray Hashemi, MD
Ray H. Hashemi, M.D., Ph.D.
Director